



Comparison of inner macular thickness and superficial macular capillary vessel density acquired using classic and high-definition optical coherence tomography angiography scans

Gábor Holló^{1,2}

¹Tutkimusz Ltd, Solymar, Hungary; ²Eye Center, Prima Medica Health Centers, Budapest, Hungary

Abstract

Background: In ophthalmology, thickness and vessel density (VD) measurements for the 6 x 6 mm inner macular retinal area have received increasing attention in glaucomatous progression research. For this area, the Angiovue optical coherence tomography system introduced a 304 x 304 A/B scans function (classic Angio Retina scan) in 2014, and a 400 x 400 A/B scans function (high-definition [HD] Angio Retina scan) in 2017. These scan types cannot be used in combination for the software provided for progression analysis.

Purpose: Since losing data for 3 years may negatively influence progression analysis, we investigated whether clinically significant differences exist between consecutive measurements acquired with these scan types on the same eyes.

Methods: As a part of our noninterventional prospective glaucoma imaging study, primary-open-angle glaucoma patients (POAG group), and ocular hypertensive and healthy control participants (structurally undamaged group) were imaged using both the classic and the HD Angio Retina scans, respectively, without changing the patients' position. High-quality images were obtained on 12 POAG

Correspondence: Gábor Holló, MD, PhD, DSc, Szel u. 5. Solymar, Hungary.
E-mail: hgbudapest@gmail.com

eyes of 12 consecutive POAG patients, and 10 healthy and ocular hypertensive eyes of 10 consecutive participants before the data collection had to be suspended due to the new coronavirus epidemic.

Results: For Early Treatment Diabetic Retinopathy Study image area, the mean difference (classic minus HD value) was $0.02 \pm 0.37 \mu\text{m}$ for inner retinal thickness ($P = 0.869$) and $0.33 \pm 1.33 \%$ ($P = 0.452$) for superficial capillary VD in the structurally normal group (between-methods difference: $\leq 0.8\%$ of the respective normal value). In the POAG group, the corresponding figures were $-0.07 \pm 1.22 \mu\text{m}$ for inner retinal thickness ($P = 0.854$; between-methods difference: 0.6% of the normal value) and $1.12 \pm 2.58 \%$ for superficial capillary VD ($P = 0.158$; classic scan value minus HD scan value: $1.12 \pm 2.58 \%$; 2.3% of the normal value).

Conclusion: Our results suggest that combined use of thickness and VD values for structurally normal eyes and thickness values for POAG eyes derived from classic and HD scans, respectively, for progression analysis can be reasonable since the differences between the corresponding values are small. However, combining the corresponding VD parameters for POAG eyes is useful only when the follow-up time before the scan type change is long enough to counterbalance the effect of the change on the result.

Keywords: Angio Retina scan, glaucoma progression analysis, high-definition scan, OCT angiography, vessel density

1. Introduction

Glaucoma is a progressive optic neuropathy and one of the leading causes of irreversible deterioration of vision and blindness worldwide.¹ In primary open-angle glaucoma (POAG), which is the predominant glaucoma type in white Europeans and people of African origin, the primary cause of the disease is an active dysregulation in the lamina cribrosa of the optic nerve head. Elevation of the intraocular pressure (IOP) worsens the development and progression of the loss of retinal ganglion cells and their axons, the retinal nerve fibers. Elevated IOP without any glaucomatous damage is also common (ocular hypertension [OHT]). In some cases, it converts to glaucoma after years, but in most cases remains a stable condition with no structural and functional damage. In glaucoma, the progressive retinal structural damage can be noninvasively measured in the retinal nerve fiber layer for retinal nerve fiber layer thickness (RNFLT) and in the inner (superficial) macula for retinal ganglion cell thickness using optical coherence tomography (OCT). The resulting functional loss is characterized and measured by means of visual field examinations. Since in POAG impaired capillary perfusion is considered an important cause of dysregulation in the optic nerve head and progressive loss of RNFLT and retinal ganglion cells,^{2,3} the recently developed noninvasive capillary

perfusion measurement (optical coherence tomography [OCT] angiography) of the various retinal layers and sectors, separately, is now in the focus of glaucoma research. One of the main research areas in OCT angiography for glaucoma is long-term progression analysis, in which capillary perfusion and structural parameters are longitudinally investigated for their capability to detect and measure POAG progression. These investigations, however, take several years, while the OCT angiography software versions are subject to continuous updates and development. This results in a special research problem: should investigators use the older (less informative) software versions during the total follow-up period or should they switch to the more informative versions? In general, in the latter case data obtained with the older software versions need to be excluded from the analysis owing to software version related differences, but this considerably reduces the follow-up time and decreases the likelihood of progression being detected. In order to keep more information for progression analysis it would be necessary to investigate the interchangeability of the corresponding parameter values obtained with the different software versions. Our current investigation addresses this point for certain OCT angiography scan types and parameters.

In recent years, inner macular thickness and superficial capillary vessel density (VD) measurements in the 6 x 6 mm diameter macular retinal area have become increasingly important in glaucoma progression research.⁴⁻⁷ The Angiovue OCT (Optovue Inc., Fremont, CA, USA) is one of the OCT angiography systems which offer macular retina scans for this area.⁸ In the Angio Retina scan mode, one image acquisition results in spatially corresponding inner (superficial) retinal thickness (ganglion cell complex [GCC]) and capillary VD values, which are provided for various sectors, image hemifields, the Early Treatment Diabetic Retinopathy Study (ETDRS) area, and the total image area, respectively.

The first (classic) version of the 6 x 6 mm Angio Retina scan was released in 2014 as a part of software version 2014.2.0.93. This classic scan comprised 304 x 304 A and B scans and 640 pixels along the Z axis. In 2017 a high-definition (HD) scan was released for the same retinal area (software version 2017.1.0.151). The HD scan comprises 400 x 400 A and B scans and 640 pixels along the Z axis. The recent software versions allow image acquisition with both scan options, but combined use of the corresponding classic and HD scan types for the software provided glaucoma progression analysis is not possible. Thus, those clinicians and researchers who started using the HD scan version, with its greater resolution and more attractive image sharpness, lost the option to use data collected between 2014 and 2017 for longer progression analysis. For the determination of structural and VD progression, a 3-year time span represents a clinically important period, in particular since the time elapsed since the introduction of any Angio Retina scan is short.

In order to clarify whether GCC thickness and capillary VD values determined with the classic 6 x 6 mm Angio Retina scan can be usefully employed in OCT

software independent, long-term progression analyses that also employ 6 x 6 mm HD Angio Retina scans, we consecutively acquired images with both scan types on the same healthy, ocular hypertensive (OHT), and POAG eyes and compared the corresponding GCC thickness and superficial capillary VD values.

2. Methods

The research protocol was approved by the Institutional Review Board for Human Research of Semmelweis University, Budapest, Hungary. Written informed consent was obtained from all participants before enrolment. All applicable institutional and governmental regulations concerning the ethical use of human volunteers were followed. All participants were white Europeans. The investigation was conducted in the Glaucoma Center of Semmelweis University in February and March 2019.

2.1. Patients

The current cross-sectional investigation formed part of our long-term prospective investigation, in which healthy, OHT, and POAG participants undergo a detailed clinical investigation, visual field testing with the Octopus Normal G2 test, and imaging using the Angiovue OCT instrument (Optovue Inc., Fremont, CA, USA) in every 6-month data collection period.⁷ The current data collection period had to be suspended due to the coronavirus epidemic. This is why we report data of 6 untreated healthy eyes of 6 consecutive healthy participants and 4 under-treatment OHT eyes of 4 consecutive OHT patients for the combined healthy and OHT group, and 12 POAG eyes of 12 consecutive POAG patients for the glaucoma group.

For inclusion in the investigation, the healthy patients required a mean defect (MD) less than 2 dB using Octopus perimetry Normal strategy, square root of Loss Variance (sLV) less than 2.5 dB, and no significantly decreased test point sensitivity value, normal optic nerve head, and untreated IOP consistently below 22 mmHg. The under-treatment OHT patients required normal optic nerve head and visual field (with MD less than 2 dB using Octopus perimetry Normal strategy, sLV less than 2.5 dB, no significantly decreased test point sensitivity value), and untreated IOP consistently above 21 mmHg in both eyes. The under-treatment POAG patients required untreated IOP consistently above 21 mmHg, open anterior chamber angle, glaucomatous neuroretinal rim loss, and a reliable and reproducible visual field defect typical for glaucoma (inferior and/or superior paracentral or arcuate scotomas, nasal step, hemifield defect or generalized depression with Octopus perimetry MD higher than 2 dB using the Normal strategy). The demographics of the patient groups (a combined normal and OHT group, and a glaucoma group) are shown in Table 1. The severity of glaucoma in the POAG group was characterized using the current visual field MD values.⁹ Eyes with an MD value ≤ 6 dB

Table 1. Demographics of the participants and eyes

	Healthy and OHT eyes (n = 10)	POAG eyes (n = 12)
Age (mean ± SD; years)	58.1 ± 16.7	63.1 ± 10.9
BCVA (mean ± SD)	1.00 ± 0.00	0.96 ± 0.14
Refractive error (spherical equivalent; mean ± SD; diopters)	0.02 ± 0.11	-1.87 ± 3.21
Number of pseudophakic eyes	1	2
IOP (mean ± SD; mmHg)	18.8 ± 3.6	18.8 ± 5.8
MD (mean ± SD; dB)	0.45 ± 1.05	8.82 ± 8.27
Mean peripapillary RNFLT (classic ONH scan, mean ± SD; μm)	94.9 ± 7.7	69.5 ± 12.5
Mean GCC thickness (classic GCC scan, mean ± SD; μm)	93.0 ± 5.2	75.8 ± 9.90

OHT: ocular hypertension; BCVA: best-corrected visual acuity; SD: standard deviation; MD: mean defect; RNFLT: retinal nerve fiber layer thickness; GCC: ganglion cell thickness

were classified as early glaucoma, eyes with an MD value between 6 and 12 dB as moderate glaucoma, and eyes with an MD value > 12 dB as advanced glaucoma.

2.2. OCT and OCT angiography imaging

All image acquisitions were made with the same Angiovue/RTVue-XR OCT instrument using software version 2017.1 with the Phase 7 update^a via undilated pupil by the same investigator (GH). The Angiovue OCT obtains amplitude decorrelation angiography images using an A-scan rate of 70,000 scans per second, a light source centered on 840 nm, and a bandwidth of 50 nm. Superficial macular capillary VD is the percentage of the area represented by red blood cell movement within the studied macular area for the GCC layer. In the current investigation, both GCC thickness and superficial macular capillary VD values were determined using the instrument’s superficial slab. During the imaging examination for each eye, two high-quality optic nerve scans for peripapillary RNFLT measurement and macular GCC scans were acquired first, and immediately afterwards two

high-quality 6 x 6-mm classic and two high-quality 6 x 6 mm HD Angio Retina scans were acquired without changing the patients' position. The Dual Track Motion Function was activated for both Angio Retina scan types. To be included in the current analysis, all study eyes had to have a Signal Strength Index 50 or higher for the optic nerve scans and GCC scans, and a Scan Quality index 7/10 or higher for both Angio Retina scans. Only images with optimal image quality, no motion artifacts, vitreous floaters, or other artifacts were selected for analysis. For each Angio Retina scan type, the image with higher Scan Quality Index was used. When both images had the same Scan Quality Index, the image acquired first was used. For both GCC thickness and capillary VD two spatially corresponding areas were investigated: the ETDRS area and the total scanned area, respectively.

2.3. Statistics

The ROPstat 2.0 program package was used for statistical analysis. Descriptive statistics are presented as means \pm standard deviations (SD). To determine the between-methods differences, the VD value provided by the HD scan was subtracted from the corresponding VD value provided by the classic scan, and the calculated difference was statistically investigated *versus* zero using the paired t-test. A *P*-value of < 0.05 was considered statistically significant.

3. Results

In the POAG group, the severity of glaucoma ranged between early and advanced based on the current visual field MD values (range: 3.2 to 23.1 dB). For each eye, the Quality Index value was the same in both scan types. The group Scan Quality Index value was 8.70 ± 0.48 and 7.58 ± 0.67 for the combined healthy and OHT eyes, and the POAG eyes, respectively. Figure 1 shows the corresponding macular OCT angiography images obtained with the classic and the HD scan for a healthy eye, and Figure 2 for a moderate severity POAG eye, respectively.

In each group, the between-scan type difference was similar for both GCC thickness and both VD parameters, respectively (Table 2). In the combined healthy and OHT group, the GCC thickness difference between the corresponding Angio Retina scans was $0.02 \pm 0.37 \mu\text{m}$ and $0.19 \pm 0.95 \mu\text{m}$ for the ETDRS and the total scan areas, respectively ($P \geq 0.544$). In the POAG group, the corresponding figures were $-0.07 \pm 1.22 \mu\text{m}$ and $0.56 \pm 1.01 \mu\text{m}$, respectively ($P \geq 0.081$). In the combined healthy and OHT eyes, the VD differences were $0.33 \pm 1.33\%$ and $0.40 \pm 1.38\%$ ($P \geq 0.380$) for the ETDRS and the total scan areas, respectively. In the POAG group, the corresponding figures were $1.12 \pm 2.58\%$ and $1.09 \pm 2.50\%$, respectively ($P \geq 0.158$).

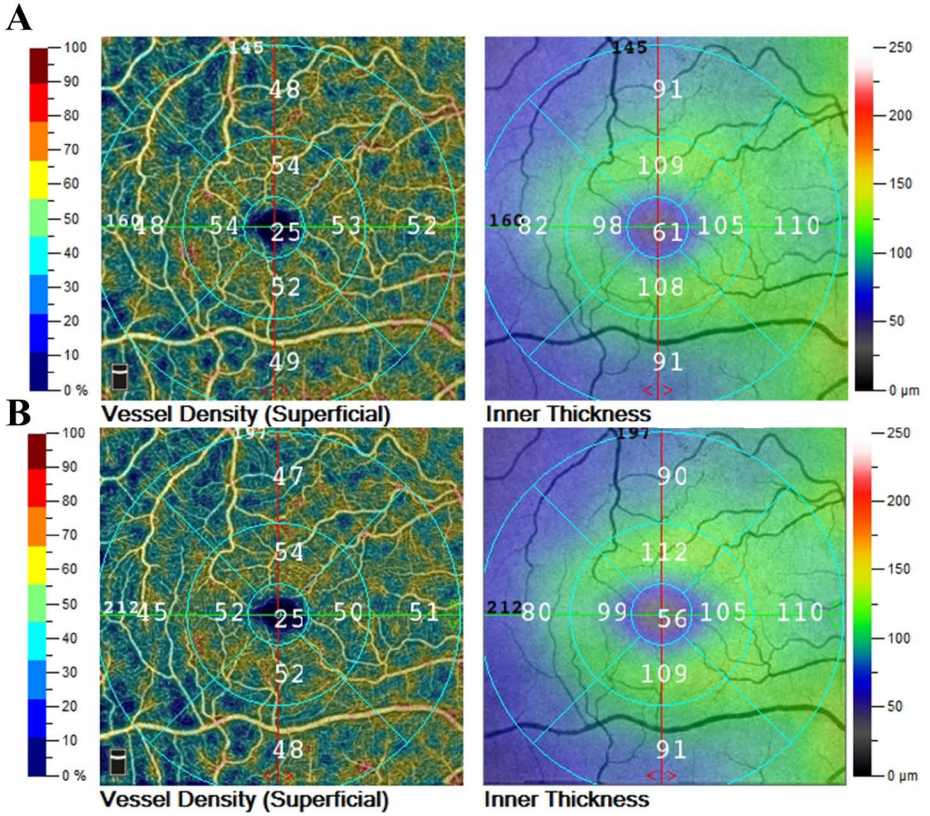


Fig. 1. Corresponding superficial macular OCT angiography images obtained with the Angiovue OCT 6 x 6 mm classic (A) and HD (B) scan, respectively, on a healthy right eye of a 67-year-old participant. The spatially corresponding capillary perfusion (vessel density, %) and thickness (inner retinal thickness, μm) sector values are indicated by both software versions on the image.

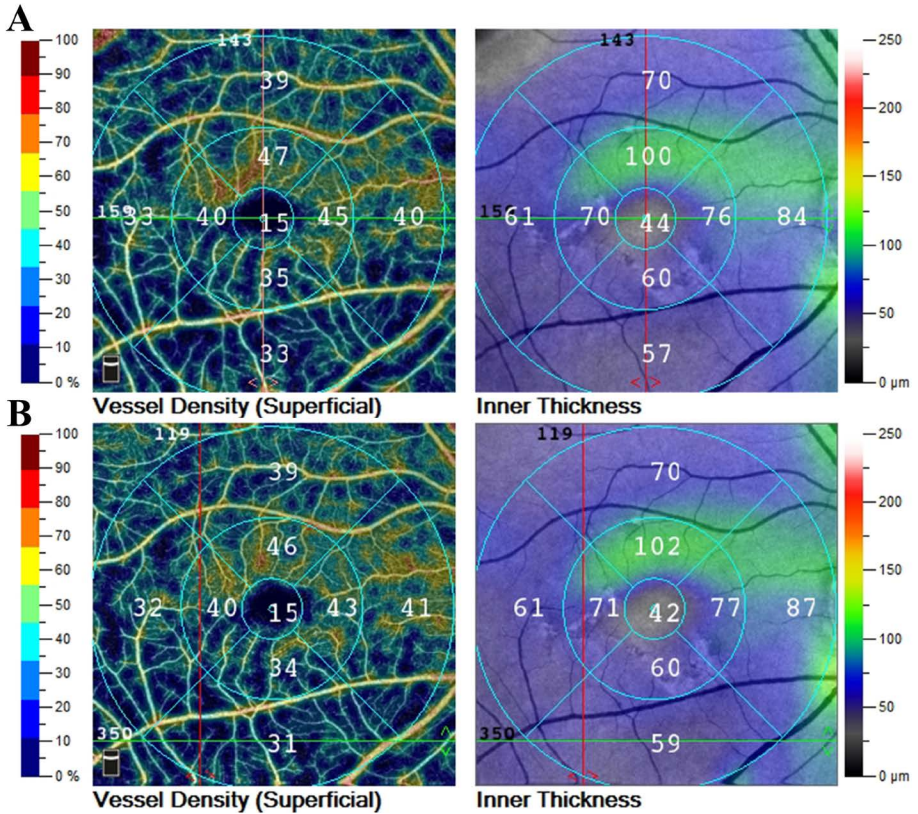


Fig. 2. Corresponding superficial macular OCT angiography images obtained with the Angiovue OCT 6 x 6 mm classic (A) and HD (B) scan, respectively, on a moderate severity POAG right eye of a 66-year-old patient. The spatially corresponding capillary perfusion (vessel density, %) and thickness (inner retinal thickness, μm) sector values are indicated by both software versions on the image.

Table 2. Comparison of the corresponding classic and HD Angio Retina scan results

	6 x 6 mm classic Angio Retina scan	6 x 6 mm Angio Retina HD scan	Difference	P-value*
Healthy and OHT eyes (n = 10)				
GCC thickness, ETDRS area (mean ± SD; μm)	95.30 ± 4.74	95.32 ± 4.83	0.02 ± 0.37	0.869
VD, ETDRS area (mean ± SD; %)	49.27 ± 2.44	49.60 ± 2.65	0.33 ± 1.33	0.452
GCC thickness, total image area (mean ± SD; μm)	94.22 ± 4.87	94.41 ± 4.65	0.19 ± 0.95	0.544
VD, total image area (mean ± SD; %)	49.11 ± 2.39	49.52 ± 2.68	0.40 ± 1.38	0.380
POAG eyes (n = 12)				
GCC thickness, ETDRS area (mean ± SD; μm)	77.19 ± 11.07	77.13 ± 11.45	-0.07 ± 1.22	0.854
VD, ETDRS area (mean ± SD; %)	40.11 ± 5.33	41.24 ± 4.98	1.12 ± 2.58	0.159
GCC thickness, total image area (mean ± SD; μm)	76.35 ± 10.29	76.91 ± 10.20	0.56 ± 1.01	0.081
VD, total image area (mean ± SD; %)	39.86 ± 4.95	40.96 ± 6.69	1.09 ± 2.50	0.158

OHT: ocular hypertension; SD: standard deviation; GCC: ganglion cell thickness; VD: vessel density; ETDRS: Early Treatment Diabetic Retinopathy Study; POAG: primary open-angle glaucoma

*Paired t-test

4. Discussion

This report investigated whether any clinically significant, systematic difference exists between the corresponding GCC thickness and superficial capillary VD values determined with the 6 x 6 mm classic and HD Angio Retina scan versions of the Angiovue OCT angiography system, respectively. The background of our investigation is that the classic scan was released 3 years earlier than the HD scan, which offers higher resolution and more attractive image appearance. The two scan types cannot be used in combination for the instrument's progression analysis function; however, progression analysis can be performed without using the OCT instrument's software, and in this case the values acquired with both scan types can be combined. However, before deciding whether to combine data acquired with the different scan versions, it is important to establish whether there is any clinically significant systematic difference between the corresponding results.

We found that in healthy and OHT eyes, the differences between the scan types were negligible for both the GCC thickness and VD parameters. For the former parameters, the mean differences were less than 0.2 μm (approximately 0.2% of the normal value). For the latter parameters, it did not exceed 0.4% (approximately 0.8% of the normal value). These results show that in healthy and OHT eyes, combining the two Angio Retina scan type values for a longer progression analysis does not represent any clinically significant bias. In the POAG group, which comprised eyes with early to advanced glaucoma cases, the mean absolute GCC thickness difference did not exceed 0.56 μm (approximately 0.6% of the normal value). However, the corresponding mean VD differences were somewhat higher ($\leq 1.12\%$), representing approximately 2.3% of the normal value. This $\leq 1.12\%$ difference is larger than the average monthly macular VD progression ($-0.199 \pm 0.073\%$) measured on POAG patients in a recent prospective Angiovue OCT angiography study within a time frame of 36.6 ± 6.4 months.¹⁰ However, OCT angiography is not performed on a monthly basis during glaucoma follow-up. Based on the -0.199% monthly progression rate value, the total VD change in a 6-month period is -1.194% , which can potentially be neutralized by the $\leq 1.12\%$ VD increase caused by change from classic to HD scan. In other words, the VD change caused by the scan type change can mask VD reduction that developed in an approximately 6-month period in POAG patients. These results suggest that, in POAG, the combined use of the corresponding classic and HD scan GCC thickness parameters will probably not cause any bias. However, combining the corresponding VD parameters offers benefits only when the follow-up time before the scan version change is considerably longer than 6 months.

Our study has limitations. Since our participants had several years of experience in OCT angiography imaging, and all eyes had clear optical media and high image quality, our results cannot be automatically applied to patients inexperienced in OCT angiography imaging, eyes with media opacities, or lower image quality. The number of eyes investigated by us is low (10 eyes for the combined healthy and OHT

group, and 12 eyes for the POAG group). This is due to the coronavirus epidemic in Europe, which made it impossible to continue with data collection. However, our close-to-zero mean between-method differences and the low SD values show that our results are clinically informative.

In summary, we found minimal differences between the classic and the HD 6 x 6 mm Angio Retina scan versions of the Angiovue OCT for the corresponding inner macular thickness values in both the combined healthy and OHT group, and the POAG group, respectively, and for the superficial VD values in the combined healthy and OHT group. This suggests that it would be reasonable to combine these corresponding measurement values acquired with these scan types for progression analysis when increasing the number of visits or the length of the follow-up period is advantageous to detect and measure glaucomatous progression. In contrast, in POAG patients, combining the superficial VD values obtained first with the classic and later with the HD scan version is recommended only when the follow-up time before the scan version switch is long enough to exceed the influence of the VD increase caused by the scan type change, *i.e.*, considerably longer than 6 months. It is also important to emphasize that for clinical decision making, the result of the combined progression analysis requires careful evaluation by an ophthalmologist for all parameters.

Declarations

Ethics approval and consent to participate

The research protocol was approved by the Institutional Review Board for Human Research of Semmelweis University, Budapest, Hungary. Written informed consent was obtained from all participants before enrolment. All applicable institutional and governmental regulations concerning the ethical use of human volunteers were followed.

Competing interests

Gábor Holló is an unpaid consultant of Optovue, Inc.

Funding

This research received no specific grant from any funding agency in the public, commercial or not-for-profit sectors.

Acknowledgements

None to declare.

References

1. Tham Y-C, Li X, Wong TY, et al. Global prevalence of glaucoma and projections of glaucoma burden through 2040: a systematic review and meta-analysis. *Ophthalmology* 2014;121:2081-90. <https://doi.org/10.1016/j.ophtha.2014.05.013>.
2. Pinto AL, Willekens K, Van Keer K, et al. Ocular blood flow in glaucoma - the Leuven Eye Study. *Acta Ophthalmol.* 2016;94:592-598. <https://doi.org/10.1111/aos.12962>.
3. Flammer J, Orgül S, Costa VP, et al. The impact of ocular blood flow in glaucoma. *Prog Retin Eye Res.* 2002;21:359-93. [https://doi.org/10.1016/s1350-9462\(02\)00008-3](https://doi.org/10.1016/s1350-9462(02)00008-3).
4. Hou H, Moghimi S, Zangwill LM, et al. Macula vessel density and thickness in early primary open-angle glaucoma. *Am J Ophthalmol.* 2019;199:120-132. <https://doi.org/10.1016/j.ajo.2018.11.012>
5. Moghimi S, Zangwill LM, Penteado RC, et al. Macular and optic nerve head vessel density and progressive retinal nerve fiber layer loss in glaucoma. *Ophthalmology.* 2018;125:1720-1728. <https://doi.org/10.1016/j.ophtha.2018.05.006>
6. Hou H, Moghimi S, Proudfoot JA, et al. Ganglion cell complex thickness and macular vessel density loss in primary open-angle glaucoma. *Ophthalmology.* 2020;127:1043-1052. <https://doi.org/10.1016/j.ophtha.2019.12.030>
7. Holló G. Comparison of thickness – function and vessel density – function relationship in the superior and inferior macula, and the superotemporal and inferotemporal peripapillary sectors. *J Glaucoma.* 2020;29:168-174. <https://doi.org/10.1097/IJG.0000000000001441>
8. Optovue Inc. RTVue XR Avanti System. User Manual International Software Version 2017.1. Release date: 11/2017.
9. Hodapp E, Parrish RK, Anderson DR. *Clinical Decisions in Glaucoma.* St Louis, MO: Mosby; 1993. pp. 52–61.
10. Ye C, Wang X, Yu MC, et al. Progression of macular vessel density in primary open-angle glaucoma: a longitudinal study. *Am J Ophthalmol.* 2020;223:259-266. <https://doi.org/10.1016/j.ajo.2020.10.008>