



---

# Filtering blebs structure and function evaluation using optical coherence tomography

Daiva Paulaviciute-Baikstiene, Renata Vaiciuliene, Ingrida Januleviciene

*Eye Clinic of Kaunas Medical Academy of Lithuanian University of Health Sciences, Kaunas, Lithuania*

## Abstract

*Purpose:* To assess the ability of a noncontact optical coherence tomography to evaluate the morphological features of filtering blebs one year after glaucoma surgery.

*Design:* Prospective study.

*Methods:* Eighteen patients (18 eyes) with diagnosed primary open-angle glaucoma (POAG) assigned for trabeculectomy were included in the 12-month study carried out in the Eye clinic of the Lithuanian University of Health Sciences. All participants underwent trabeculectomy with 5-fluorouracil (5-FU). Bleb function was considered to be successful if the intraocular pressure (IOP) was  $\leq 18$  mmHg without glaucoma medications and a limited success if:  $18 < \text{IOP} \leq 21$  mmHg with or without glaucoma medications at 12 months after surgery.

The filtering blebs were imaged by anterior segment optical coherence tomography (AS-OCT) to evaluate the bleb wall reflectivity and measured bleb structures 12 months after trabeculectomy. Level of significance:  $p < 0.05$  was considered significant.

*Results:* The mean preoperative IOP was 25.7 (6.5) mmHg and the mean number of topical glaucoma medications was 3.0 (1.2). After surgery the mean IOP was 13.8 (3.4) mmHg and glaucoma medication was 0.3 (1.0) (Wilcoxon test,  $p < 0.001$ ).

Analyzing bleb morphology and bleb function it was found that with uniform wall reflectivity 0 out of 3 eyes (0%) had successful bleb function and with multiform wall reflectivity 14 out of 15 eyes (93.3%) had successful bleb function 12 months after surgery ( $p = 0.005$ ).

---

**Correspondence:** Daiva Paulaviciute-Baikstiene, Eye Clinic of Kaunas Medical Academy of Lithuanian University of Health Sciences, Eivenių g. 2A, LT 50009, Kaunas, Lithuania. E-mail: daiva\_paulaviciute@yahoo.com

---

We found positive correlation between IOP changes and bleb wall thickness, height of internal fluid-filled cavity (bleb height) and total bleb height ( $r = 0.875, 0.897, 0.939, p < 0.001$ ).

*Conclusion:* AS-OCT is a useful device to assess the structure of the filtering bleb. Larger internal fluid-filled cavity, total bleb height, bigger bleb wall thickness and multiform bleb wall reflectivity were found to be good indicators of bleb function.

*Key words:* AS-OCT, intraocular pressure, filtering bleb, primary open-angle glaucoma, trabeculectomy

## 1. Introduction

Trabeculectomy is indicated for eyes with POAG that have an inadequate IOP with maximum tolerated medical therapy. The principle of the surgery is to reduce IOP by circumventing the outflow tract and allowing aqueous humor to exit beneath the scleral flap and under the conjunctiva where it forms a filtering bleb.<sup>1</sup> The success of this surgery depends on the functionality of the filtering bleb, aqueous humor drainage and IOP lowering effect.<sup>2</sup> However, in a significant number of cases aqueous humor filtration does not occur, because of obstruction of intrascleral aqueous flow and bleb fibrosis.<sup>3</sup> Bleb morphology has always been an important clinical parameter as an indicator for bleb function.<sup>2</sup> The description of bleb morphology and function is usually based on clinician's subjective judgment. Bleb appearance, as assessed by slit-lamp biomicroscopy, is widely used to predict the possible functionality and the structure of blebs, but it is difficult to see internal structures, which may have an effect on bleb function.<sup>3</sup>

Cross-sectional imaging modality such as AS-OCT with high axial resolution (18  $\mu\text{m}$ ), allows to see the bleb's internal structures, improves the analysis of the function of filtering blebs<sup>4-6</sup> and gives additional information of the morphology.<sup>7-10</sup> Understanding the bleb function, objectively identifying and quantifying early signs of failure after glaucoma surgery, would enable clinicians to choose proper treatment and/or preclude possible complications such as bleb leak or scarring, blebitis, and bleb-related endophthalmitis.<sup>11-13</sup>

It is important to know what features of mature blebs are associated with bleb function. The purpose of the present study was to assess the ability of OCT to evaluate morphological features of filtering blebs one year after trabeculectomy with 5FU. We aimed to find the correlation between AS-OCT and functional outcomes by describing morphological features of successful and limited success blebs.

## 2. Methods

This prospective study was performed in the Eye clinic of the Lithuanian University of Health Sciences. Eligible patients with POAG were recruited between January and December 2014. The study was conducted in accordance with the ethical standards of the Declaration of Helsinki and approved by Kaunas clinical research ethics committee. Written informed consent was obtained from all the patients.

The inclusion criteria were POAG patients over 18 years with medically uncontrolled IOP and progressing glaucoma, scheduled for surgical treatment. Pregnant or nursing women, patients with uncontrolled systemic diseases, previous ocular surgery, secondary glaucoma, congenital glaucoma and patients with a history of other eye diseases or trauma were excluded from the study.

Goldmann applanation tonometry was performed before and 12 months after surgery. An average of three separate IOP measurements was taken.

All participants underwent trabeculectomy with 5-FU. In all cases a fornix-based conjunctival flap was created, after which a sponge soaked in 5-FU was applied to the sclera. A scleral flap of approximately 5 x 5 mm was made. After trabeculectomy the scleral flap was closed with several (4-5) nylon 10-0 sutures. The conjunctiva was closed with a nylon 10-0 running suture.

Bleb function was considered to be successful if IOP was  $\leq 18$  mmHg without glaucoma medications and a limited success if:  $18 < \text{IOP} \leq 21$  mmHg with or without glaucoma medications 12 months after surgery.

The filtering blebs were examined by slit-lamp biomicroscopy, photography and by AS-OCT (Nidek, RS-3000). This optical device is adapted to analyze the anterior segment of the eye. Work principle is based on low coherence interferometry, which measures the delay and intensity of backscattered infrared light using a super luminescent diode with a six-mm tissue penetration and the reflection signal at a wavelength of approximately 1310 nm.<sup>14</sup>

Patients were asked to look down, and the upper lid was manually elevated to expose the bleb as much as possible for better visualization and taking care to avoid pressure on the globe or bleb.

All blebs were assessed by wall reflectivity. Depending on the presence or absence of hyporeflexive spaces in the bleb wall we divided blebs into the multiform or uniform. There was noted presence of small hyporeflexive areas (various sizes and shapes fluid-filled spaces) in blebs with multiform walls. Uniform blebs wall looked hyperreflective (no visible fluid filling spaces in the wall).<sup>15</sup>

Bleb structures (wall thickness, total height, length and height of internal fluid-filled cavity (bleb length and height)) were evaluated in the AS-OCT images (Fig. 1). The optical aperture of the AS-OCT was centered to the maximal elevation of the filtering bleb with the aid of a joystick. Then four standard AS-OCT images (vertical, horizontal, oblique to the right, oblique to the left) were obtained simultaneously for each bleb and one randomly chosen section was used for analysis.

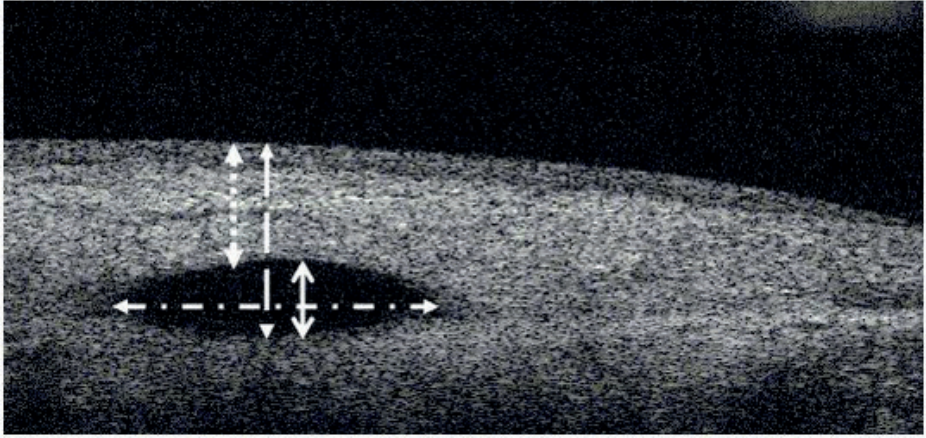


Fig. 1. Parameters describing bleb morphology: wall thickness (dot line), total bleb height (dash line), bleb height (solid line); bleb length (dash-dot line).

The AS-OCT images were evaluated in order to assess bleb morphologic features by a single, skilled observer (D.P.B), who was blinded to the clinical data.

Statistical analysis were performed using SPSS version 20.0 for Windows (IBM Corporation, Armonk, NY, USA). Qualitative variables were described as arithmetic mean and standard deviation (M (SD)). In this pilot study, variables of patients were described using the general statistical concepts for small sample size of the position, distribution and symmetry. The level of significance  $p \leq 0.05$  was considered significant.

The Kolmogorov-Smirnov test was used to test for normal distribution. Preoperative and postoperative data were analyzed with the nonparametric Wilcoxon test for continuous variables (IOP, number of glaucoma medications) and chi-square test for categorical variables (correlation of bleb wall morphology with bleb functions). To calculate a difference in IOP reduction between multiform and uniform filtering blebs, Mann-Whitney test was performed. Correlation between IOP reduction and bleb structure parameters was analyzed using the Spearman's correlation.

### 3. Results

Eighteen eyes of 18 patients (13 males (66.7%) and six females (33.3%)) with a mean age of 67.5 (7.8) were included in the study.

The mean preoperative IOP was 25.7 (6.5) mmHg after trabeculectomy decreased to 13.8 (3.4) mmHg (Wilcoxon test,  $p < 0.001$ ) (Fig. 2). The mean number of topical glaucoma medications at the preoperative visit was 3.0 (1.2) and 0.3 (1.0) after surgery (Wilcoxon test,  $p < 0.001$ ). According to surgical outcome success criteria there were 14 (77.8%) successful blebs (mean IOP = 12.4 (2.4) mmHg) and 4 (22.2%)

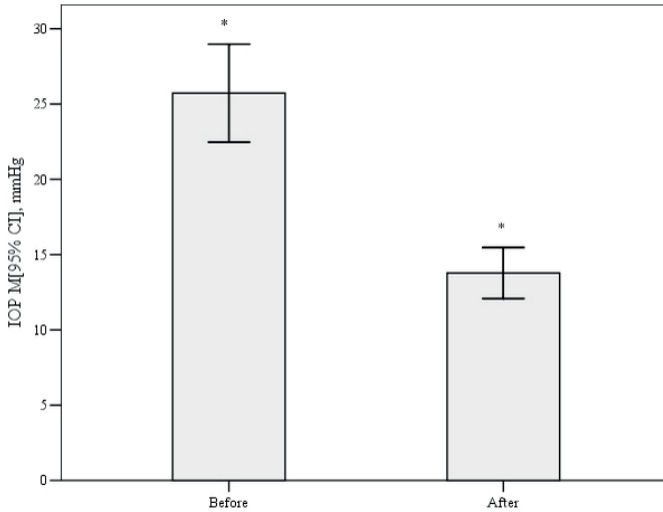


Fig. 2. IOP reduction 12 months after trabeculectomy. \*  $p < 0.001$  by Wilcoxon test.

limited success (mean IOP = 18.5 (1.7) mmHg).

Uniform bleb wall reflectivity was in three eyes (16.7%) and multiform in 15 eyes (83.3%). Analyzing bleb morphology and function it was found that none of blebs with uniform wall reflectivity has successful function. While blebs with multiform wall reflectivity 93.3% had successful function at 12 months ( $p = 0.005$ ) (Table 1).

One year after surgery decrease in IOP was statistically significantly higher in eyes with multiform as compared to uniform bleb wall reflectivity ( $p = 0.008$ ) (Fig. 3).

Measurements of bleb structure are shown in Figure 4. We found positive correlation between IOP changes and bleb wall thickness ( $r = 0.875$ ,  $p < 0.001$ ), height of internal fluid-filled cavity ( $r = 0.897$ ,  $p < 0.001$ ) and total bleb height ( $r = 0.939$ ,  $p < 0.001$ ) (Fig. 5).

Table 1. Correlation of bleb wall morphology with bleb functions at 12 months after surgery.

Bleb wall reflectivity/function	Success (%)	Limited success (%)	Total (%)
Uniform	0 (0)	3 (16.7)	3 (16.7)
Multiform	14 (93.3)	1 (6.7)	15 (83.3)
Total (%)	14 (77.8)	4 (22.2)	18 (100)

$p = 0.005$  by Chi-square test.

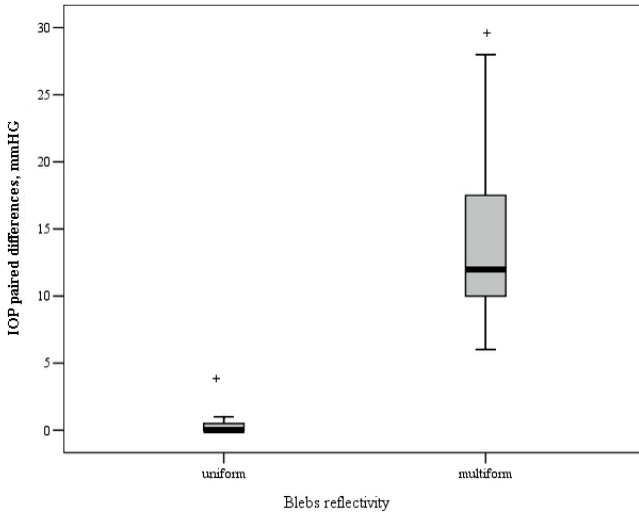


Fig. 3. IOP changes after trabeculectomy depending on bleb wall morphology. + p = 0.008 by Mann-Whitney Test.

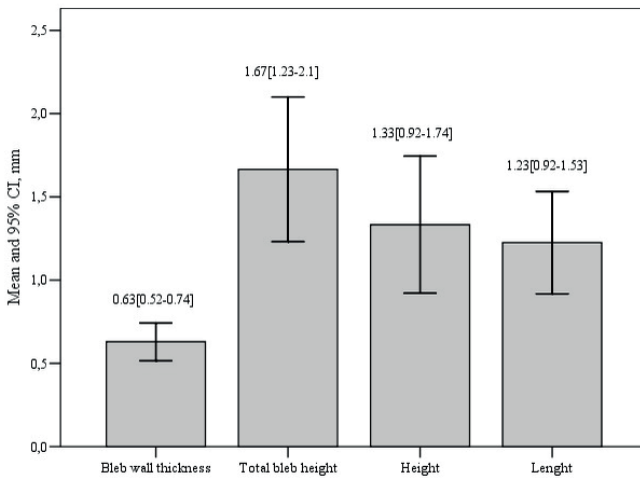


Fig. 4. Bleb structure measurements (mean and 95% CI).

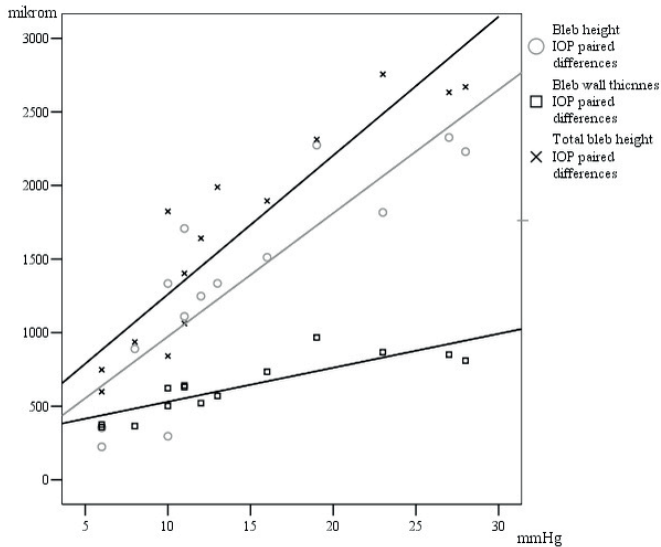


Fig. 5. Scattergram showing the relationship between the changes of IOP and bleb structure parameters. Spearman`s correlation: O 0.897,  $p < 0.001$ ;  $\square$  0.875,  $p < 0.001$ ;  $\times$  0.939,  $p < 0.001$ .

## 4. Discussion

We found that the vast majority of investigated eyes (93.3%) retained multiple layer appearance (areas of hyporeflectivity) and had good bleb function 12 months after the glaucoma surgery. It has been reported that most of the filtering blebs found on AS-OCT imaging, with good IOP control had thicker bleb walls with microcysts, wider hyporeflective areas and higher blebs.<sup>10,17-24</sup> Several studies used a variety of cross-sectional imaging modalities (e.g., UBM or AS-OCT) and found associations between bleb wall reflectivity and bleb function.<sup>14-24</sup> It is known that it is possible from AS-OCT images to recognize features that may help to find the process and location of bleb failure.<sup>10</sup> Ciancaglini et al. observed that successful blebs reveal a low bleb wall reflectivity.<sup>4</sup> Filtering blebs showed average bleb wall thickness 0.51 mm, height of internal fluid cavity 0.67 mm in observational case-series study of Devika *et al.*<sup>24</sup> In our successful cases bleb wall thickness were 0.63 mm, height of internal fluid cavity 1.35 mm. Our advantage is that we also measured the length and the total height of the filtering bleb. Results suggested that higher IOP reduction and better bleb function were associated with higher bleb, bigger wall thickness and total height. Contrarily Tominaga *et al.* did not find any correlation between the IOP and height of bleb cavity. However a negative correlation was found between postoperative IOP and bleb wall thickness.<sup>25</sup>

The limited success blebs had a non-thickened, low bleb wall, high reflectiv-

ity between the conjunctiva and scleral flap, a small spaces beneath the flap and occluded internal ostium.<sup>26</sup> These small optically empty spaces beneath the flap inform about the level of aqueous outflow interrupting process between the sclera and subconjunctival space.<sup>10</sup> Another useful information is thickness of bleb wall after the surgery. It possibly reflects flow of aqueous through conjunctiva-episclera.<sup>25</sup>

IOP control after trabeculectomy depends on both the aqueous outflow to the bleb and its absorption from the bleb.<sup>2</sup> In our study, a mean IOP reduction was 46.3% after the surgery. Singh et al. in a prospective cross-sectional study revealed that in successful cases mean IOP was 12.2 (2.9) mmHg with no ocular hypotensive medications. In failed cases, mean IOP was 17.9 (2.0) mmHg.<sup>27</sup> Our study shows similar results. Mean IOP was 12.4 (2.4) mmHg in successful cases, and 18.5 (1.7) in limited success cases. This proves that trabeculectomy is very effective surgical method for the majority of glaucoma patients.

Napoli and coworkers reported that the reflectivity of filtering blebs associated very well to the postoperative IOP and to the reduction of IOP.<sup>28</sup> Based on IOP and glaucoma medication criteria we determined that successful blebs had multiform wall reflectivity while limited success blebs had uniform wall reflectivity. Furthermore, multiform bleb wall reflectivity had higher IOP change from baseline 12 months after the surgery.

Nakano and colleagues observed that uniform bleb wall reflectivity in the early postoperative period associated with worse function of the mature bleb. This information might predict future bleb failure. They also noticed that there is no correlation between IOP of developing blebs and blebs function at six months.<sup>3</sup>

It is known that high wall reflectivity indicated scarring of the bleb.<sup>29</sup> The success of trabeculectomy depends on the long-term preservation of the aqueous drainage, healing process and the use of 5-FU and mitomycin C.<sup>29,30</sup> These antimetabolites are used to prevent fibrosis and significantly lowers high scarring of the bleb by reducing the population of goblet cells.<sup>32,32</sup>

The detection of early postoperative scarring and the continuing development of surgical measures to reduce this risk represent a major challenge of filtering surgery.

Possible limitations of our study are small sample size and relatively short follow-up. A small number of limited success blebs, may have influenced the significance of statistical findings in this group. Limitation of the AS-OCT is the disability to image bleb vascularity, which may be an important prognostic factor of bleb survival postoperatively.

Further long-term studies are needed in order to evaluate stabilization of glaucoma progression based on morphological parameters of filtering blebs.



## 5. Conclusion

Anterior segment imaging is a valuable tool in the detailed assessment of the morphological changes in the bleb tissue. Larger internal fluid-filled cavity, total bleb height, bigger bleb wall thickness and multifiform bleb wall reflectivity were found to be good indicators of bleb function. These findings may aid clinicians to predict surgical treatment outcomes and to make correct decisions regarding postoperative bleb management.

## References

1. Weinreb RN, Crowston JG. Glaucoma surgery: Open-angle glaucoma. WGA Consensus Series 2, pp. 57-62. The Netherlands: Kugler Publications 2005.
2. Wells AP, Crowston JG, Marks J, Kirwan JF, Smith G, Clarke JC, et al. A pilot study of a system for grading of drainage blebs after glaucoma surgery. *J Glaucoma* 2004;13:454-460.
3. Nakano N, Hangai M, Nakanishi H, et al. Early trabeculectomy bleb walls on anterior-segment optical coherence tomography. *Graefes Arch ClinExpOphthalmol* 2010;248(8):1173-1182.
4. Ciancaglini M, Carpineto P, Agnifili L, et al. Filtering bleb functionality: a clinical, anterior segment optical coherence tomography and in vivo confocal microscopy study. *J Glaucoma* 2008;17:308-317.
5. Pfenninger L, Schneider F, Funk J. Internal reflectivity of filtering blebs versus intraocular pressure in patients with recent trabeculectomy. *Invest Ophthalmol Vis Sci* 2011;52:2450-2455.
6. Picht G, Grehn F. Classification of filtering blebs in trabeculectomy: biomicroscopy and functionality. *Curr Opin Ophthalmol* 1998;9:2-8.
7. Hirooka K, Takagishi M, Baba T, Takenaka H, Shiraga F. Stratus optical coherence tomography study of filtering blebs after primary trabeculectomy with a fornix-based conjunctival flap. *Acta Ophthalmol* 2010;88:60-64.
8. Babighian S, Papizzi E, Galan A. Stratus-OCT of filtering bleb after trabeculectomy. *Acta Ophthalmol Scand* 2006;84:270-271.
9. Savini G, Zanini M, Barboni P. Filtering blebs imaging by optical coherence tomography. *Clin Experiment Ophthalmol* 2005;33:483-489.
10. Singh M, Chew PT, Friedman DS, et al. Imaging of trabeculectomy blebs using anterior segment optical coherence tomography. *Ophthalmology* 2007;114:47-53.
11. Hu CY, Matsuo H, Tomita G, et al. Clinical characteristics and leakage of functioning blebs after trabeculectomy with mitomycin-C in primary glaucoma patients. *Ophthalmology* 2003;110:345-352.
12. DeBry PW, Perkins TW, Heatly G, et al. Incidence of late onset bleb-related complications following trabeculectomy with mitomycin. *Arch Ophthalmol* 2002;120:297-300.
13. Soltau JB, Rothman RF, Budenz DL, et al. Risk factors for glaucoma filtering bleb infections. *Arch Ophthalmol* 2000;118:338-342.
14. Yamamoto T, Sakuma T, Kitazawa Y. An ultrasound biomicroscopic study of filtering blebs after mitomycin C trabeculectomy. *Ophthalmology* 1995;102:1770-1776.
15. McWhae JA, Crichton AC. The use of ultrasound biomicroscopy following trabeculectomy. *Can J Ophthalmol* 1996;31:187-191.
16. Avitabile T, Russo V, Uva MG. Ultrasound-biomicroscopic evaluation of filtering blebs after laser suture lysis trabeculectomy. *Ophthalmologica* 1998;212:17-21.
17. Jinza K, Saika S, Kin K, Ohnishi Y. Relationship between formation of a filtering bleb and an intrascleral aqueous drainage route after trabeculectomy: evaluation using ultrasound biomicroscopy.

- Ophthalmic Res 2000;32:240-243.
18. Savini G, Zanini M, Barboni P. Filtering blebs imaging by optical coherence tomography. *Clin Experiment Ophthalmol* 2005;33:483-489.
  19. Babighian S, Rapizzi E, Galan A. Stratus OCT of filtering bleb after trabeculectomy. *Acta Ophthalmol Scand* 2006;84:270-271.
  20. Müller M, Hoerauf H, Geerling G, et al. Filtering bleb evaluation with slit-lamp-adapted 1310-nm optical coherence tomography. *Curr Eye Res* 2006;31:909-915.
  21. Leung CK, Yick DW, Kwong YY, et al. Analysis of bleb morphology after trabeculectomy with Visante anterior segment optical coherence tomography. *Br J Ophthalmol* 2007;91:340-344.
  22. Kawana K, Kiuchi T, Yasuno Y, Oshika T. Evaluation of trabeculectomy blebs using 3-dimensional cornea and anterior segment optical coherence tomography. *Ophthalmology* 2009;116:848-855.
  23. Addicks EM, Quigley HA, Green R, Robin AL. Histologic characteristics of filtering blebs in glaucomatous eyes. *Arch Ophthalmol* 1983;101:795-798.
  24. Devika K, Girija K, Sindhu S. Analysis of bleb morphology after trabeculectomy with anterior segment optical coherence tomography. *Kerala J Ophthalmol* 2014;26(1):48-52.
  25. Tominaga A, Miki A, Yamazaki Y, Matsushita K, Otori Y. The assessment of the filtering bleb function with anterior segment optical coherence tomography. *J Glaucoma* 2010; 19(8):551-555.
  26. Zhang Y, Wu Q, Zhang M, et al. Evaluating subconjunctival bleb function after trabeculectomy using slit lamp optical coherence tomography and ultrasound biomicroscopy. *Chin Med J* 2008;121(14):1274-1279.
  27. Singh M, See JL, Aquino MC, Thean LS, Chew PT. High-definition imaging of trabeculectomy blebs using spectral domain optical coherence tomography adapted for the anterior segment. *Clin Experiment Ophthalmol* 2009;37(4):345-351.
  28. Napoli PE, Zucca I, Fossarello M. Qualitative and quantitative analysis of filtering blebs with optical coherence tomography. *Can J Ophthalmol* 2014;49(2):210-216.
  29. Khalili MA, Diestelhorst M, Kriegelstein GK. Langzeit untersuchungen von 700 Trabekulektomien. *Klin Monatsbl Augenheilkd* 2000;217:1-8.
  30. Picht G, Mutsch Y, Grehn F. Nachbetreuung von Trabekulektomien. *Ophthalmologie* 2001;7:629-624.
  31. Bindlish R, Condom GP, Schlosser MS, et al. Efficacy and safety of mitomycin-C in primary trabeculectomy. *Ophthalmology* 2002;109:1336-1342.
  32. Katz GL, Higginbotham EJ, Lichter PR, et al. Mitomycin C versus 5 fluorouracil in high risk glaucoma filtering surgery. Extended follow up. *Ophthalmology* 1995;102:1263-1269.